



# Xanthogranulomatous Cystitis: A Rare Clinical Case

✉ Gürkan Cesur<sup>1</sup>, ✉ Tarık Yonguç<sup>1</sup>, ✉ Enver Vardar<sup>2</sup>

<sup>1</sup>University of Health Sciences Turkey, İzmir Bozyaka Training and Research Hospital, Clinic of Urology, İzmir, Turkey

<sup>2</sup>University of Health Sciences Turkey, İzmir Bozyaka Training and Research Hospital, Clinic of Pathology, İzmir, Turkey

## Abstract

Xanthogranulomatous cystitis is a rare benign chronic inflammatory disease of unknown etiology. We report a 77-year-old male whose treatment is complete endoscopic resection. Patient was asymptomatic at three months follow-up after treatment.

**Keywords:** Cystitis, macrophages, urinary bladder neoplasms

## Introduction

Xanthogranulomatous changes have been reported at multiple sites in the urinary system (1), with the kidney being the most common organ. Histologically, there are multinucleated giant cells, lipid-laden macrophages, and cholesterol clefts. Although, xanthogranulomatous cystitis (XC) is an uncommon, chronic, benign inflammatory disease of unknown etiology and was first defined in 1932 (2). It is usually diagnosed as a papillary lesion in the bladder, but lateral wall enrolment is very rare. In this case report, we want to present a patient who had XC because of the pathology of the transurethral resection performed for the papillary lesion on the lateral and posterior bladder wall.

## Case Report

A 77-year-old male hospitalized with urgency, frequency, dysuria, hematuria symptoms for nine months period. He has been with urethral catheterized for 6 months due to lower urinary tract obstructive symptoms. The patient was immobile because of paraplegia for 3 years. Hematological and biochemical examinations were normal. Urinalysis showed 23 leukocytes and 580 erythrocytes per high power field. Urine culture was sterile. Urinary ultrasonography revealed diffuse bladder wall thickness (13 mm) and echogenic foci in the posterior wall. Abdomen computed tomography revealed diffuse of the bladder wall thickening, papillary lesions on the right lateral and posterior wall of the bladder and a giant fecaloma in the rectum (Figure 1). During the cystoscopy, multiple polypoid formations with a cotton-like appearance were observed on the bladder posterior

and right lateral wall (Figure 2). Complete endoscopic resection was performed; the postoperative course was uneventful.

In pathological assessment xanthogranulomatous macrophage cells were positive for periodic acid schiff mark for calcospherules (Michaelis - Guttman bodies). Acid fast bacteriath mark was negative. CD68 immunohistochemically stained strongly, however, cytokeratin was negative (Figure 3). According to these findings, the patient was diagnosed with XC. That findings did not support malignancy. The patient was given antibiotic prophylaxis for 3 months. At a follow-up after three months there was no recurrence. Patient consent was obtained for this case report.

## Discussion

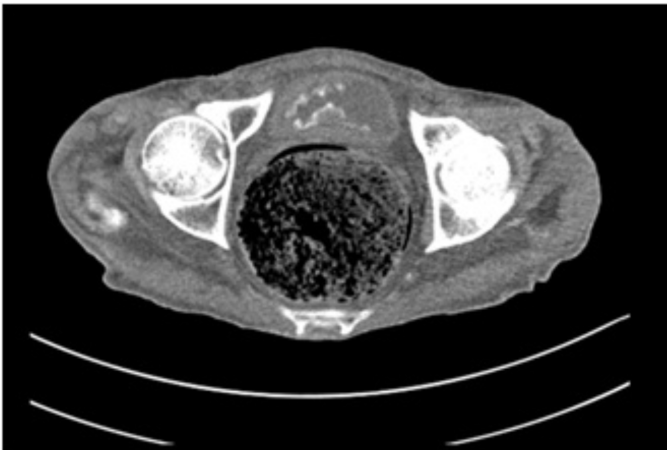
XC is an extremely rare benign chronic inflammatory disease. The first case was published by Wassiljew in 1932 (2). There are 28 XC cases in the literature and most of the cases were urachal remnants and cysts. There are no specific signs of the disease rather than cystitis like symptoms, abdominal pain, occasional hematuria and umbilical discharge. The importance of XC in the bladder is that these symptoms can be confused with bladder cancer. Also, XC in the bladder with papillary lesions can mimic bladder cancer. Accordingly, it is very important to accurately evaluate the pathological results and diagnose the disease.

The XC etiology has not been clarified yet. There are many theories highlighting immunological disorders (3,4), unusual lipid metabolism (5) and urothelial metaplasia resulting from chronic infection (6). Here, the lesions on the right lateral and posterior wall of the bladder showed that they were not caused

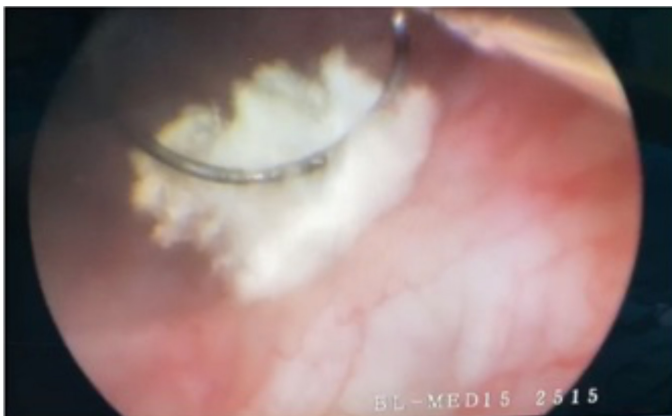**Cite this article as:** Cesur G, Yonguç T, Vardar E. Xanthogranulomatous Cystitis: A Rare Clinical Case. Bull Urooncol 2022;21(4):142-143

**Address for Correspondence:** Gürkan Cesur, University of Health Sciences Turkey, İzmir Bozyaka Training and Research Hospital, Clinic of Urology, İzmir, Turkey  
**Phone:** +90 538 700 74 65 **E-mail:** gurkancesur1992@hotmail.com **ORCID-ID:** orcid.org/0000-0001-9089-3452

**Received:** 02.09.2020 **Accepted:** 06.02.2021



**Figure 1.** Polypoid masses on bladder right and inferior wall in computerized tomography



**Figure 2.** Cystoscopy reveals cotton-like appearance on the floor and right wall of bladder

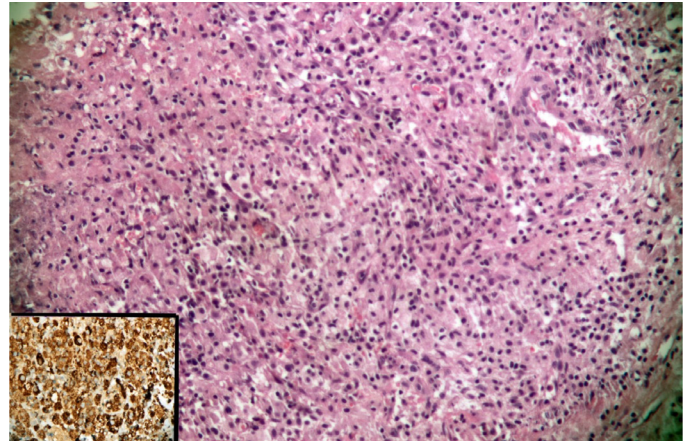
by the urachus anomaly. As the patient had a urethral catheter for 6 months, chronic irritation of the catheter may have been in this case.

## Conclusion

In the XC of the bladder, medical treatment is unsuccessful therefore conservative treatment is uncommon. Although partial resection was performed 22 cases in the literature, the most effective treatment for small lesions is complete endoscopic resection. The etiology of XC is unclear. Although the urine culture was negative, giving antibiotics may be helpful for preventing the disease.

## Acknowledgements

**Publication:** The results of the study were not published in full or in part in form of abstracts.



**Figure 3.** Histological examination of the resection specimen revealed abundant histiocytes and other chronic inflammatory cells consisting of xanthogranulomatous cystitis (H and E stains 200x magnification). Additionally CD68 were diffuse positive in histiocytes (inset-x400 magnification)

**Contribution:** There are no contributors who may not be listed as authors.

**Conflict of Interest:** No conflict of interest was declared by the authors.

**Financial Disclosure:** The authors declared that this study received no financial support.

## Ethics

**Informed Consent:** Patient consent was obtained for this case report.

**Peer-review:** Externally peer-reviewed.

## Authorship Contributions

Surgical and Medical Practices: T.Y., Concept: G.C., E.V., Design: T.Y., Data Collection or Processing: G.C., Analysis or Interpretation: E.V., Literature Search: T.Y., Writing: G.C.

## References

1. Bates AW, Fegan AW, Baithus SI. Xanthogranulomatous cystitis associated with malignant neoplasms of the bladder. *Histopathology* 1998;33:212-215.
2. Wassiljew AI. Über Erkrankungen Des urachus. *Z Urol Chir* 1932;35:199-212.
3. Walther M, Glenn JF, Vellios F. Xanthogranulomatous cystitis. *J Urol* 1985;134:745-746.
4. Chung MK, Seol MY, Cho WY, et al. Xanthogranulomatous cystitis associated with suture material. *J Urol* 1998;159:981-982.
5. Thannhauser SJ. Xanthomatosis. In: *Lipidosis: Diseases of the intracellular Lipid Metabolism*. New York: Grune and Stratton; 1958. p. 1987.
6. Hitzig WH, Seger RA. Chronic granulomatous disease: A heterogeneous syndrome. *Hum Genet* 1983;64:207-215.