



A Pregnant Female with a Rare Entity: Giant Adrenal Cyst

✉ Fatih Çolak¹, ✉ Ayhan Arslan², ✉ İlke Onur Kazaz¹

¹Karadeniz Technical University Faculty of Medicine, Department of Urology, Trabzon, Turkey

²Akçaabat Haçkalı Baba State Hospital, Clinic of Urology, Trabzon, Turkey

Abstract

Diagnosis of an adrenal cyst is not a frequent conclusion. Being usually small in size and asymptomatic, may make them underdiagnosed. Although adrenal cysts are thought to be found in all ages, a total of only 18 pregnant patients having adrenal cysts were reported until now. In this article, a pregnant woman with a 184x132 mm adrenal cyst filling the right suprarenal area is presented and the relevant literature is reviewed.

Keywords: Adrenal cyst, pregnant, laparoscopy, giant

Introduction

It was considered that Greiseliuss described the first benign adrenal cyst, in 1670. The description was based on autopsy findings of a 45-year old patient who had rupture of the cyst (1). Adrenal cysts, being uncommon, are predominantly small and asymptomatic, and can be found in any age (2). Pregnant females, reported to have adrenal cysts, were very rare, with only a total of 18 pregnant patients having adrenal cysts were presented until now (3). Here, we present a pregnant woman with a giant adrenal cyst.

Case Report

The obstetrician of the 31-year old patient having 27 weeks of gestation found a large mass in the upper right quadrant of the abdomen. The patient was referred to urology for further work-up. In physical examination, besides the findings related to pregnancy, a large mass in the upper right quadrant of the abdomen was palpated. Blood chemistry was totally normal and endocrinological values showed no abnormality. Ultrasonographic examination was commented as a hemorrhagic cyst, possibly of liver origin. An magnetic resonance imaging (MRI) study was conducted and revealed a 184x132 mm cyst in right adrenal area, displacing the right kidney, concluding to a diagnosis of giant adrenal cyst (Figure 1, 2). With no signs related to a malignant potential, with no endocrinological activity and with no symptoms, the patient was offered a delayed intervention to be performed in the period after delivery with close follow-up of the cyst.

The following 12 weeks, in which a scheme of routine physical examination and serum electrolyte measurements and ultrasonographic examinations in every 4th week was chosen as the follow-up method, were uneventful, and no significant volume change of the cyst was observed in three consecutive examinations. At the 39th week of gestation, the patient gave birth to a live female child with a mass of 2940 grams. Six weeks after the delivery, without a suspicion for hydatid disease, a laparoscopic operation was planned and performed. Due to the size of the cyst, a Hutchinson approach was thought to be appropriate. The cyst was found to be related to the adrenal gland but not related to neither the kidney nor the liver. A total excision of the cystic lesion with sucking of all the cystic fluid of 4250 mL, accompanied by a partial adrenalectomy was completed during the surgical procedure. The patient was hospitalized for three days. The results of the cytological and histopathological examinations were consistent with the diagnosis of an adrenal cyst. The results obtained from histochemical staining were as follows: calretinin (+), synaptophysin [focal (+)], rcc (-), CK7 (-), CD31 [(-) except vessel walls], concluding to a diagnosis of an adrenal pseudocyst.

The patient was held on follow-up, the last visit being on the 18th month of the operation with no problems.

Informed consent was obtained from the patient.

Discussion

Less than 500 cases of adrenal cyst were reported in the literature (3). Only 18 of them were diagnosed during pregnancy. The

Cite this article as: Çolak F, Arslan A, Kazaz İO. A Pregnant Female with a Rare Entity: Giant Adrenal Cyst. Bull Urooncol 2022;21(3):110-112

Address for Correspondence: Ayhan Arslan, Akçaabat Haçkalı Baba State Hospital, Clinic of Urology, Trabzon, Turkey

Phone: +90 544 494 69 73 **E-mail:** ayhanarslan128@gmail.com **ORCID-ID:** orcid.org/0000-0001-9779-4297

Received: 18.09.2021 **Accepted:** 09.12.2021

increase in the use of imaging modalities during medical visits, led to an increase in incidental diagnosis of adrenal cysts (4). Adrenal cysts, being asymptomatic usually, are predominantly diagnosed incidentally, nowadays and are evaluated in four categories: parasitic cysts, endothelial cysts, epithelial cysts, and pseudocysts (5). Symptomatic cases may have the symptoms because of the dimension or the localisation of the cysts. Only a very small group of patients was found to be endocrinologically active. Also, not so often, a malignant lesion was described (6).

In cases with a cystic lesion with a suspicion about being adrenal cyst, the first step was described to be excluding malignant potential. Later, an endocrinological activity was to be ruled out. Symptomatic patients may need intervention, as well as an asymptomatic patient with a cyst with a huge diameter. Adrenal cysts with a diameter of 10 cm or more were accepted as giant adrenal cysts, necessitating surgical intervention.

The patient, presented here, had no suspicion of a malignant lesion and had no endocrinological activity. She was asymptomatic, but with a giant adrenal cyst. The intervention was an unavoidable situation, with the pregnancy of the patient kept in mind. In order not to risk the fetus and the mother, a postponed surgery was offered to the patient, who accepted to be in close follow-up. Literature review showed that 3 of the 18 pregnant patients had delayed intervention, while the remaining 15 had the surgical procedure during pregnancy period. Worth to mention that half of the 18 patients had a preoperative diagnosis other than an adrenal cyst, having the diagnosis through histopathological examination (3,7). Similar findings led to a conclusion that pregnant females with cystic lesion should undergo an MRI study to reveal the pathology (8). It was stated that in male patients or in female patients without pregnancy, a computed tomography study may have high accuracy for the diagnosis (9).

Data about a volume change in an adrenal cyst during pregnancy period is lacking, and also a scheme for a follow-

up during the mentioned period is not approved. We tried to manage the follow-up period with ultrasonographic examinations in every 4th week until delivery accompanied by routine physical examinations and serum electrolyte measurements. In a patient with a decision of delayed surgical intervention, a follow-up scheme seems necessary, while immediate surgical intervention during the pregnancy period may be another choice necessitating no follow-up scheme. Trauffer and Malee (10) reported that surgical interventions related to adrenal cysts had no negative effect on the course of pregnancy. On the other hand, Tait et al. (11) reported a case with adrenal cyst surgery, ending with premature delivery of a 995 grams baby who was discharged from hospital after a three-month period with bronchopulmonary dysplasia. It must be kept in mind that emergency laparotomy procedures in the pregnancy period had a 40% premature delivery or abortus rate (12). We found no signs related to a malignant potential and no endocrinological activity in the presented patient. Also, she was neither hypertensive nor hypokalemic and was free from symptoms of a cardiac failure. So, she was offered a delayed intervention to be performed in the period after delivery but with close follow-up. We, as the group managing the presented patient, felt satisfied keeping her away from intervention during the pregnancy period and performing the definitive treatment as soon as puerperal period ended with no problems.

The histopathological examination of the excised lesion have utmost importance in excluding a malignant activity and in categorising the cystic lesion. The findings of the presented patient; with synaptophysin positivity leading us to a neuroendocrine origin, with calretinin positivity leading us to an adrenocortical origin while excluding pheochromocytoma and renal cell carcinoma, with rcc negativity excluding renal cell carcinoma, with CD31 negativity excluding an endothelial origin, with CK7 negativity excluding an epithelial origin, made us conclude the diagnosis as an adrenal pseudocyst.

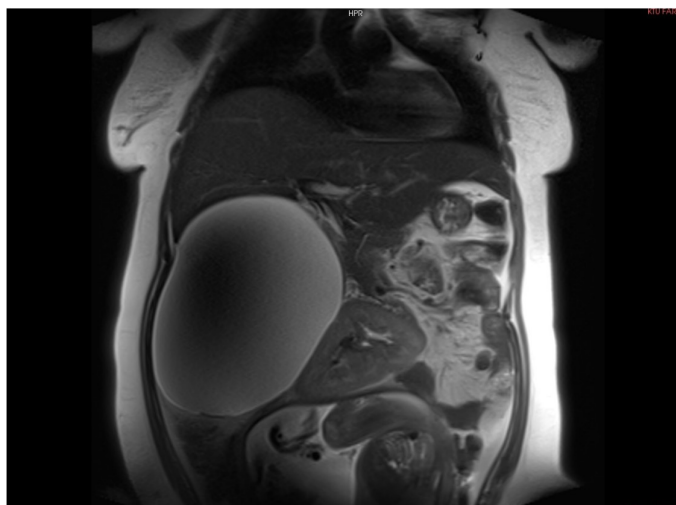


Figure 1. Coronal image of the adrenal cyst, displacing the right kidney (obtained from MRI studies)

MRI: Magnetic resonance imaging

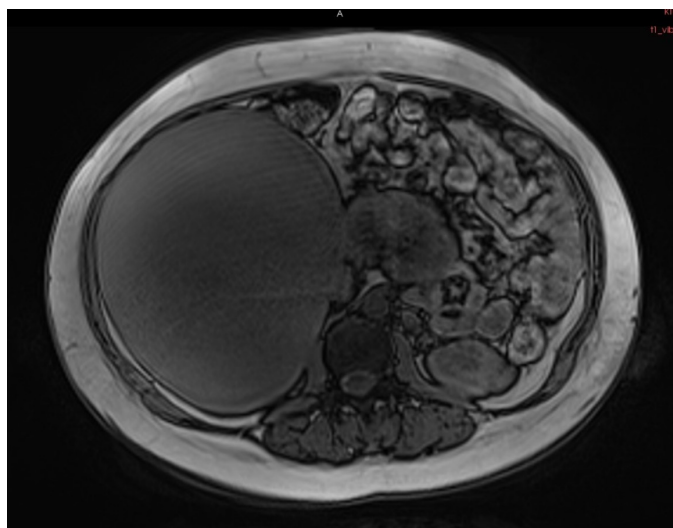


Figure 2. Axial image of the adrenal cyst, filling the right half of the abdomen (obtained from MRI studies)

MRI: Magnetic resonance imaging

Conclusion

Abdominal masses, discovered during pregnancy, needs complete evaluation in order to find the true origin. Ultrasonographic studies may present valuable data. However, MRI study of the abdomen is highly recommended in pregnant females. The definitive treatment for adrenal cysts, diagnosed during pregnancy, with no suspicion of malignancy and with no endocrinological activity, may be postponed, but with close follow-up, to decrease the risks for the fetus and the mother.

Acknowledgements

Publication: The results of the study were not published in full or in part in form of abstracts.

Contribution: There is not any contributors who may not be listed as authors.

Conflict of Interest: No conflict of interest was declared by the authors.

Financial Disclosure: The authors declared that this study received no financial support.

Ethics

Informed Consent: Informed consent was obtained from the patient.

Peer-review: Externally and internally peer-reviewed.

Authorship Contributions

Concept: F.Ç., Design: F.Ç., Supervision: İ.O.K., Data Collection-Processing: F.Ç., Analysis-Interpretation: A.A., Literature Review: F.Ç., A.A., Writing: A.A., Critical Review: İ.O.K.

References

1. Wedmid A, Palese M. Diagnosis and treatment of the adrenal cyst. *Curr Urol Rep* 2010;11:44-50.
2. Balci O, Kuscu E. Giant adrenal cyst in a pregnant woman: a case report. *J Obstet Gynaecol Res* 2008;34:399-401.
3. Mandato VD, Mastrofilippo V, Kuhn E, et al. Adrenal Cyst in Pregnancy: A Surgical Emergency. *Urology* 2018;121:22-28.
4. Milsten MS, Minielly JA, VanSchoyck P, Forrest JB. Abdominal pain secondary to a lymphangiomatous cyst of the adrenal: case report and review of literature. *J Okla State Med Assoc* 1994;87:225-227.
5. Ellis FH Jr, Dawe CJ, Clagett OT. Cysts of the adrenal glands. *Ann Surg* 1952;136:217-227.
6. Brindley GV Jr, Chisolm JT. Cystic tumors of the adrenal gland associated with Cushing's syndrome. *Tex State J Med* 1951;47:234-237.
7. Araki K, Hakariya T, Shida Y, et al. [A Case of Giant Adrenal Endothelial Cyst that was Discovered in Pregnancy and Caused Bleeding Three Years Later]. *Hinyokika Kyo* 2019;65:7-11.
8. Lazarus E, Mayo-Smith WW, Mainiero MB, Spencer PK. CT in the evaluation of nontraumatic abdominal pain in pregnant women. *Radiology* 2007;244:784-790.
9. Raj MH, Mullins JN, Chi JM, et al. The utility of abdominopelvic CT in pregnant patients with abdominal pain and a negative or inconclusive abdominal MRI. *Clin Imaging* 2020;59:88-94.
10. Trauffer PM, Malee MR. Adrenal pseudocyst in pregnancy. A case report. *J Reprod Med* 1996;41:195-197.
11. Tait DL, Williams J, Sandstad J, Lucci JA. Benign adrenal cyst presenting in a pregnant patient. *Am J Perinatol* 1997;14:461-464.
12. Sherard GB 3rd, Hodson CA, Williams HJ, et al. Adnexal masses and pregnancy: a 12-year experience. *Am J Obstet Gynecol* 2003;189:358-362; discussion 362-363.